



## Delayed and prolonged coma after acute disulfiram overdose

S. LEMOYNE<sup>1</sup>, J. RAEMAEKERS<sup>1</sup>, J. DAEMS<sup>2</sup> and L. HEYTENS<sup>1</sup>

<sup>1</sup>Dienst Intensieve Zorg, Sint-Augustinus, Wilrijk; <sup>2</sup>Psychiatric Centre Bethanië, Zoersel, Belgium

### Abstract

*We report the case of a 35 year old man presenting with a delayed and prolonged coma due to an intentional overdose with disulfiram without simultaneous alcohol ingestion. The clinical features – comprising a severe toxic encephalopathy with coma and convulsions, in combination with a quadriparesis outlasting the loss of consciousness – are summarized, and the physiopathology is reviewed.*

**Key words:** Disulfiram; encephalopathy; overdose; quadriparesis.

### Introduction

Disulfiram (Antabuse®) has been used in the management of alcoholism for over half a century. In combination with alcohol, disulfiram produces the so-called disulfiram-ethanol reaction (DER) which is the result of increased acetaldehyde levels generated by metabolism of ethanol by alcohol dehydrogenase in the liver.

Acetylaldehyde normally does not accumulate because it is cleared rapidly by metabolism via aldehyde dehydrogenase. Disulfiram blocks this enzyme, irreversibly inhibiting the oxidation of acetaldehyde and causing a manifold increase in acetaldehyde levels after ethanol consumption. The discomfort (headache, facial flushing, tachycardia, nausea,...) associated with acetaldehyde accumulation is intended to serve as a negative stimulus for alcohol aversion therapy.

Too intense an interaction between disulfiram and ethanol can cause toxicity, which is the most prevalent and best known toxic reaction of disulfiram. But disulfiram may exert direct life-threatening toxic effects, as illustrated in this case of an intentional disulfiram overdose.

### Case report

This male patient, born in 1972, was known to suffer from schizophrenia since childhood. Over the last few years the major paranoid delusions had been brought under control with antipsychotic treatment. He also had a history of toxicomania for both illicit drugs and alcohol. The latter was complicated by a polyneuropathy and an episode of convulsions due to withdrawal. Disulfiram was successfully administered as alcohol aversion therapy since the year 2000. A lower limb electromyogram performed in 2004 still showed a decrease in sensory conduction velocity, but absence of denervation activity. His recent medication consisted of disulfiram 400 mg/d, clorazepam 15 mg three times a day, olanzapine velotabs 10 mg twice a day, carbamazepine 200 mg/d, risperidone 50 mg IM every fortnight and vitamin-B supplements.

When admitted to the hospital he presented with somnolence, slight dysarthria, blurred vision, myoclonias and ataxia of the four limbs, but without muscle weakness. He admitted to having tried to commit suicide by ingesting 50 tablets of disulfiram (20 g for a 70 kg bodyweight, or 0.3 g/kg) and 'several' tablets of carbamazepine. He denied recent alcohol intake. Laboratory tests revealed a moderate hyponatraemia (127 meq/L). Disulfiram quantitative dosage could not be realized as there is no valid test available in Belgium. No activated charcoal was given. Ethanol was less than 0.1 g/L; the acid-base balance was normal. Urine toxicological screening was negative for barbiturates, amphetamines, metamphetamine, MDMA, cannabinoids, cocaine and opiates. Brain-CT did not reveal any abnormalities. The electroencephalogram showed severe diffuse slowing with theta and delta waves, compatible with a metabolic encephalopathy, and absence of 'epileptic waves'. He was treated with normal saline to correct the hyponatraemia. Because of the

myoclonias and a moderate degree of agitation, oral diazepam 5 mg three times per day was started. His consciousness – although waxing and waning – slowly deteriorated over the ensuing 48 hours and respiration became laborious with suspicion of aspiration pneumonia. He was electively intubated 48 hours after admission and transferred to our intensive care unit (day 2 post-ingestion).

The first few hours after admission to our unit the patient presented with rapidly successive myoclonias on the right side of his body, and occasionally both legs. EEG showed intermittent diffuse bursts of spikes and waves and was felt to be highly suggestive of epileptic activity. Lorazepam 0.1 mg/kg was administered and valproic acid started (loading dose 20 mg/kg over 30 min followed by 2000 mg/24 hours). Repeat brain-CT did not show any morphological abnormalities. Control of the carbamazepine level on the third day after the suicide attempt showed a close to normal value (13.2 mg/L) ruling out any serious toxic effect resulting from this compound.

Spontaneous hypothermia to 34.9°C was present on day 3 which necessitated active rewarming with a heating blanket for 4 days, after which his body temperature remained within normal limits.

Throughout admission a pronounced quadriplegia was present with virtual absence of motor response to painful stimuli and absence of peripheral reflexes.

MRI performed on day 6 (T1, T2, FLAIR, diffusion, MP-rage after Gadolinium) could not detect any abnormal signal intensities in cortex, white matter or basal ganglia and was considered normal.

Because of a serum ammonia level of 287 micromole/L (normal range 9–33 micromole/L) on day 7 after admission valproic acid was stopped and phenytoin started. Except for the elevated ammonia level due to valproic acid administration (with a value of 62.9 micromole/L 2 days later) liver function tests were normal during his stay in our unit.

Lumbar puncture fluid on day 9 showed normal cell-, glucose- and protein content. Herpes simplex culture was negative.

Fourteen days after the ingestion of the medication a slowly progressive recovery in consciousness was noted. The patient started to open his eyes and responded accurately – although at first only intermittently – to simple commands. His muscular strength clearly remained diminished. On day 17 the patient could be successfully extubated after which a more or less coherent conversation was possible. Muscular force of the left arm appeared only slightly less than normal; the right hand and arm were weaker and needed support to be held against

gravity. Finger-nose test showed ataxia and lack of coordination. He could lift his knees, but not extended legs from the bed and could not support his proper body weight. He complained about blurred vision and diplopia.

Two days later he was transferred to the referring hospital. One week later a consultant ophthalmologist reported normal vision and no signs of optic neuritis. The control electroencephalogram at this time was still considered to be abnormal with diffuse slow-wave theta-rhythm, however less so than at the time of admission.

Follow-up neurological exam after 10 months showed a good clinical recovery. His psychiatric situation remained stable and was treated as before. He reported normal strength in both arms and legs, and normal vision. To our knowledge, a control EMG was not realized.

## Discussion

Disulfiram is a long known drug used for alcohol aversion therapy which is based on its interference with ethanol metabolism (Vanden Bussche *et al.*, 2007). Ethanol is mainly metabolized in the liver by alcohol dehydrogenase to acetaldehyde, in turn oxidized to acetate by aldehyde dehydrogenase (ALDH). Disulfiram irreversibly inhibits the oxidation of acetaldehyde by competing with the cofactor nicotinamide adenine dinucleotide (NAD) for binding sites on ALDH. The precise molecular mechanism is based on the formation of an intramolecular disulfide bond at the active site of the enzyme, resulting in its inhibition (Lipsky *et al.*, 2001). Ultimately, disulfiram reduces the rate of oxidation of acetaldehyde, causing a 5- to 10-fold increase in the concentration of acetaldehyde. The increased acetaldehyde level is thought to produce the unpleasant side effects e.g. nausea, flushing, palpitations, vertigo, hypotension and headache.

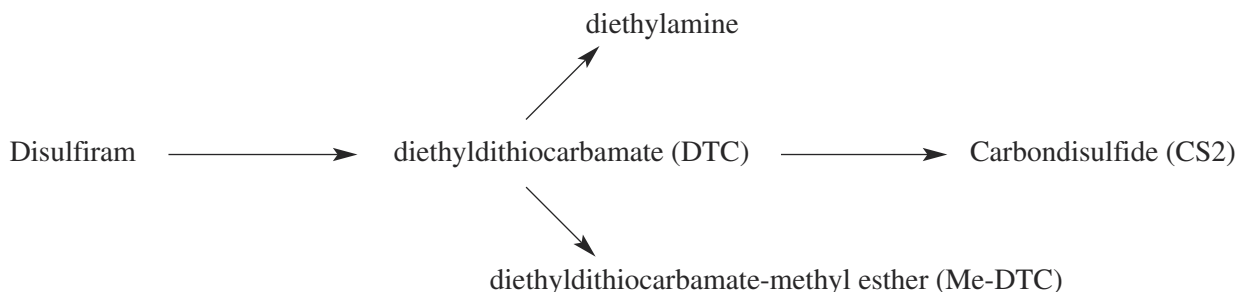
Most case reports of acute disulfiram ‘toxicity’ concern adults having ingested disulfiram together with alcohol. Occasionally significant adverse reactions are elicited by unknowingly administering alcohol, such as is the case with IV-cotrimoxazole (containing 10% ethanol as solubilising agent), diphenhydramine syrup or foods containing alcohol (vinegars). The clinical symptoms seen in our patient were due to an intentional overdose of disulfiram alone, without concurrent alcohol ingestion.

Disulfiram is highly lipid soluble and has 80% bioavailability after an oral dose. Approximately 5–20% is not metabolized and is excreted unchanged in the faeces; the remainder is metabolized to toxic

and non-toxic metabolites. The elimination of disulfiram and its metabolites is a very slow process. Approximately 20% of the drug remains in the body for 1-2 weeks post-ingestion. This explains to an important extent the protracted clinical course of an intoxication with this compound.

Disulfiram toxicity may be classified into 1) hepatotoxicity, 2) optic neuritis, 3) peripheral neuropathy with either sensory, motor or combined deficits and 4) encephalopathy with a range of

expressions from psychosis, dystonia, convulsions to coma, and with possible permanent chronic neuropsychological impairment (Ryan *et al.*, 1993). The underlying mechanism is incompletely understood as the metabolism of the drug is complex. Disulfiram is metabolized to diethyldithiocarbamate (DTC) which is methylated to form S-methyl DTC (MeDTC), and a secondary degradate carbon disulfide (CS<sub>2</sub>).



Alone, disulfiram is relatively non-toxic. However, it inhibits most of the hepatic microsomal enzymes (cytochrome P450), and interferes with the metabolism of certain drugs (e.g. coumadin, benzodiazepines, theophyllin, phenytoin, caffeine, tricyclic antidepressants). Consequently, elevated serum levels ensue and corresponding toxicity may occur.

Hepatotoxicity has been reported during chronic treatment, most often within 2 months from the start of treatment. The course of the hepatitis can be fulminant and has been reported to be fatal in 30% of the cases. This liver necrosis is idiosyncratic and not dose related (Dupuy *et al.*, 1995). There are no convincing reports of hepatic necrosis after acute intoxication.

Optic neuritis has been rarely reported, usually after several months of normal dosage of disulfiram and most often recovering within 2 months (Boukriche *et al.*, 2000; Bessero *et al.*, 2006).

Diethyldithiocarbamate (DTC), the most active metabolite of disulfiram, impairs the activity of brain dopamine beta-hydroxylase, an enzyme that catalyzes the metabolism of dopamine to norepinephrine. DTC thus causes depletion of presynaptic norepinephrine and accumulation of dopamine (Bourdélát-Parks *et al.*, 2005). This dopamine agonism is thought to be the mechanism underlying both the hypotension and altered behaviour associated with disulfiram toxicity. DTC has also been reported to selectively and specifically block the NMDA receptor subtype of the glutamate receptors (Ningaraj *et al.*, 2001).

The ability of DTC to chelate copper may provide another mechanism for the neurotoxicity seen with both acute intoxication and chronic use of disulfiram. Lesions of the basal ganglia have been described in patients with extrapyramidal symptoms after therapy with disulfiram (Krauss *et al.*, 1991; Laplane *et al.*, 1992). It has been hypothesized that abnormal accumulation of copper in the CNS, leading to oxidative stress and neuronal cell death, is responsible for this.

Carbon disulfide (CS<sub>2</sub>), a secondary DTC degradate, has also been suggested to be responsible for the lesions of basal ganglia by inducing a severe microangiopathy (Chuang *et al.*, 2007). In addition to its neurotoxic effects (neurobehavioral toxin), CS<sub>2</sub> is hepatotoxic, inhibits cytochrome P-450, and is cardiotoxic.

The peripheral neuropathy appears to be dose dependent with both motor, sensory or mixed deficits occurring as early as 10 days after beginning therapy but most often with a time interval of 5 to 6 months. Segmental demyelination of axons has been reported in rats exposed to DTC for 8 weeks (Tonkin *et al.*, 2003).

A few case reports mention a pronounced flaccid quadriplegia after acute disulfiram intoxication (Hirschberg *et al.*, 1987; Zorzon *et al.*, 1995). This was also the case in our patient with motor weakness outlasting the period of coma. Recovery of sensory and motor function usually takes place but is slow, and may be incomplete. Follow-up in our patient showed a full recovery. An EMG was not performed.

It is likely that this pronounced muscle weakness in combination with the progressive loss of consciousness played a role in the aspiration pneumonia and prolonged need for ventilatory support.

Breath may have an odour of garlic or sulphur following therapeutic use and is the result of the presence of acetone and carbon disulphide which are mainly excreted through the lungs. This was also observed in our patient on day 2. This finding is the basis of a breath test to assess compliance with disulfiram therapy (Fletcher *et al.*, 2006).

Therapy of a disulfiram overdose is mainly supportive. Shortly after ingestion of disulfiram, administration of repeated doses of activated charcoal is recommended in order to minimise the reabsorption of disulfiram and its metabolites from the gastrointestinal tract. Symptomatic treatment with oxygen, IV-fluids, intubation to protect the airway in cases of coma, and benzodiazepines for seizures may be necessary. Hemodialysis is not indicated for disulfiram overdose. Thiamine can be used to overcome the shortage of pyridoxine caused by the carbon disulfide metabolite. The evidence for this however is scarce.

### Conclusion

Although toxic effects of disulfiram are mostly seen after ingestion of disulfiram in combination with alcohol, acute overdosing of disulfiram alone may lead to life-threatening poisoning. Toxicity is due to long lasting accumulation of several metabolites with strong chelating activity for metals, interference with mitochondrial enzymes in both the central nervous system and peripheral nerves, dopamine agonism and direct neurotoxic effects.

It is important to be aware of the slow onset and protracted course of a disulfiram intoxication. Both vigilance at the onset of symptoms, and persistence during the course of this intoxication are warranted since the encephalopathy as well as the polyneuropathy appear to be most often reversible.

### REFERENCES

Bessero AC, Daeppen JB, Borruat FX. Optic neuropathy while taking disulfiram. *J Fr Ophthalmol.* 2006;29:924-928.

Boukriche Y, Weisser I, Aubert P, Masson C. MRI findings in a case of late onset disulfiram-induced neurotoxicity. *J Neurol.* 2000;247:714-715.

Bourdélát-Parks BN, Anderson GM, Donaldson ZR, Weiss JM, Bonsall RX. *et al.* Effects of dopamine

beta-hydroxylase genotype and disulfiram inhibition on catecholamine homeostasis in mice. *Psychopharmacology (Berl).* 2005;183:72-80.

Chuang WL, Huang CC, Chen CJ, Hsieh YC, Kuo HC. *et al.* Carbon disulfide encephalopathy: cerebral microangiopathy. *Neurotoxicology.* 2007;28:387-393.

Dupuy O, Flocard F, Vial C, Rode G, Charles N. *et al.* Disulfiram (Espéral) toxicity: A propos of 3 original cases. *Rev Med Interne.* 1995;16:67-72.

Fletcher K, Stone E, Mohamad M, Faulder G, Faulder R. *et al.* A breath test to assess compliance with disulfiram. *Addiction.* 2006;101:1705-1710.

Hirschberg M, Ludolph A, Grottemeyer KH, Gullotta F. Development of a subacute tetraparesis after disulfiram intoxication. *Eur Neurol.* 1987;26:222-228.

Krauss JK, Mohadjer M, Wakhloo AK, Mundinger F. Dystonia and akinesia due to pallidoputaminial lesions after disulfiram intoxication. *Mov Disord.* 1991;6:166-170.

Laplane D, Attal N, Sauron B, de Billy A, Dubois B. Lesions of basal ganglia due to disulfiram neurotoxicity. *J Neurol Neurosurg Psychiatry.* 1992;55:925-929.

Lipsky JJ, Shen ML, Naylor S. Overview-in vitro inhibition of aldehyde dehydrogenase by disulfiram and metabolites. *Chem Biol Interact.* 2001;130-132:81-91.

Ningaraj NS, Chen W, Schloss JV, Faiman MD, Wu JY. S-methyl-N,N-diethylthiocarbamate sulfoxide elicits neuroprotective effect against N-methyl-D-aspartate receptor-mediated neurotoxicity. *J Biomed Sci.* 2001;8:104-113.

Ryan TV, Sciara AD, Barth JT. Chronic neuropsychological impairment resulting from disulfiram overdose. *J Stud Alcohol.* 1993;54:389-392.

Tonkin EG, Valentine HL, Zimmerman LJ, Valentine WM. Parenteral N,N-diethylthiocarbamate produces segmental demyelination in the rat that is not dependent on cysteine carbamylation. *Toxicol Appl Pharmacol.* 2003;189:139-150.

Vanden Bussche L, Vanacker R, Heylens G. Behandeling van aan alcohol gebonden psychiatrische stoornissen: het gebruik van disulfiram, *Tijdschrift voor Geneeskunde.* 2007;63:609-615.

Zorzon M, Mase G, Biasutti E, Vitrani B, Cazzato G. Acute encephalopathy and polyneuropathy after disulfiram intoxication. *Alcohol Alcohol.* 1995;30:629-631.

L. Heytens,  
Dienst Intensieve Zorg Sint-Augustinus,  
Oosterveldlaan 24,  
2610 Wilrijk (Belgium).  
E-mail: Luc.heyten@gza.be